

OFFICE OF THE MEDICAL SUPERINTENDENT,  
ALLIED HOSPITAL FAISALABAD.  
Ph: 041-9210082  
Fax 041-9210083  
E.mail:ahf\_fsd@yahoo.com

No. / 359/31907 /AHF/15  
Dated F/Abad 3-8 /2015

To  
The Addl: Registrar (Judl)  
Lahore High Court, Lahore.


Subject:- WRIT PETITION / CRL NO. 22496-15 MST. NUSRAT VS HOME DEPARTMENT.

Kindly refer to letter No. 047550 dated 28.07.2015 on the above subject.


Please find enclosed medical examination report in respect of condemned prisoner Abdul Basit S/O Allah Ditta as submitted by Dr. Ghazanfar Ali Sandhu, Associate Professor, Medical Unit-1, Chairman of medical board.

Endst: No. 359/31907-9

Copy forwarded to:-

  
MEDICAL SUPERINTENDENT,  
ALLIED HOSPITAL, FAISALABAD.  
/AHF/15 Dated 3-8 /2015

1. The Assistant Advocate General, Punjab, Lahore High Court, Lahore with reference to his letter No. 11542-48 dated 28.05.2015.
2. The Superintendent, Central Jail, Faisalabad.

  
MEDICAL SUPERINTENDENT,  
ALLIED HOSPITAL, FAISALABAD.

The Medical Superintendent,  
Allied Hospital, Faisalabad.

Subject:-


**OPINION OF MEDICAL BOARD OF PRISONER REFERRED BY  
CENTRAL JAIL FAISALABAD.**


With reference to the letter No. 159/31221-25/AHF/15 dated 29-07-2015 and Assistant Advocate General, Punjab Lahore letter No. 16238-AG.Pb dated 28.07.2015 & Superintendent Central Jail, Faisalabad Letter No. 11542-48 Dated 28.05.2015, regarding the Medical Examination of the condemned Prisoner Mr. Abdul Basit S/o Allah Ditta, Caste Malik Awan (Baloch) R/O Chak No. 220/RB, Shahbaz Town, District, Faisalabad. He was examined by Medical Board held on 01.08.2015.


The Patient was diagnosed as Tuberculous Meningitis in 2010 and he was given full treatment. He developed paraplegia as complication of Tuberculous meningitis. His further investigations showed atrophy of spinal cord with no surgical lesion. His weakness did not improve after treatment. He is on supportive therapy and rehabilitation since then.

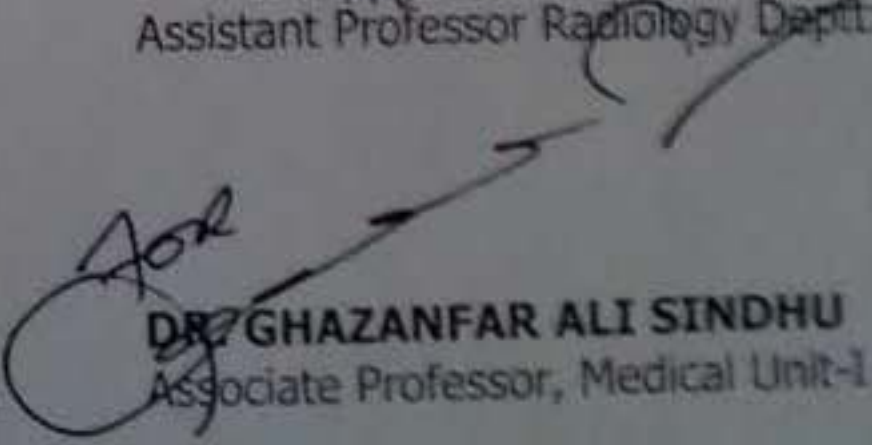
At this moment, he is having 0/5 power in lower limbs and 4/5 power in upper limbs. He is bed bound with urinary and fecal incontinence.

In our opinion, Patients with ~~this~~ condition are usually permanently disabled and there is almost no chance of any recovery. He is likely to remain bed bound for his life.

  
**DR. JAVAID IQBAL**  
Neurophysion, Medical Unit-I

  
**DR. ANJUM MEHDI**  
Assistant Professor Radiology Deptt.

  
**DR. NAZAR HUSSAIN**  
Associate Professor, Neurosurgery Unit-I  
Assistant

  
**DR. GHAZANFAR ALI SINDHU**  
Associate Professor, Medical Unit-I